Positive apraclonidine test in sudden onset of painful Horner syndrome caused by carotid artery dissection

Prueba positiva de apraclonidina en aparición súbita del síndrome de Horner doloroso causado por disección de la arteria carótida

Dra. María Amparo Manyari Cárdenas
Musgrove Park Hospital, Reino Unido

Our Patient

- PC: 36y male, 1d H/O sudden onset L side headache with painful neck and painful ear.
- Headache related w/flashing lights and slight dizzy sensation.
- Later added L ache behind eye

Our Patient

- Suffers of migraine/concerned as never had pain in the ear before
- Next day patient LUL swollen, eye looks red but less painful/ ° diplopia
- Pupils seem different
- ? Blurred vision

History

- POH: none
- PMH: Sinusitis/Migraine/ °H/o previous trauma
- FH: -ve
- SH: smoker 15/day-works as a chef
- Allergies/intolerances: morphine
- Meds: none. Took Paracetamol and not relief.

Exam

- VA: 6/4 BE unaided (1.25 decimal equivalent)
- AS: L hyperemia/°discharge/quiet
- IOPs: 9mm Hg BE
- Full ocular movement
- Pupils: °RAPD

Exam

- Ishihara color test: normal
- Anisocoria / OS miosis
- °LUL ptosis/ °anhidrosis/ °heterochromia
- ? L enophthalmos but not very obvious
- Pupils: OD bright 4/dim 6
  OS bright 3/dim 5
- Fundus: NAD

Exam

- T° 34 °C BP 143/94 p 57’
- ENT assessment was normal
- ° carotid bruits
- Pharmacological test

Pharmacological test

- Apraclonidine 1%
- Pupils:

  OD bright 4/dim 6 After drops: 3

  OS bright 3/dim 5 After drops 4
- Diagnosis: L painful Horner's Sx

Differential diagnosis

- ? Dissecting Carotid Aneurysm
- ? Pancoast tumor
- ? Migraine
- ? Clustered headaches

Exam

- Admitted for observation and investigation
- CXR
- FBC, U+e
- MRI head and neck/MRA
- Medication: Aspirin 75mg

Chest X Rays

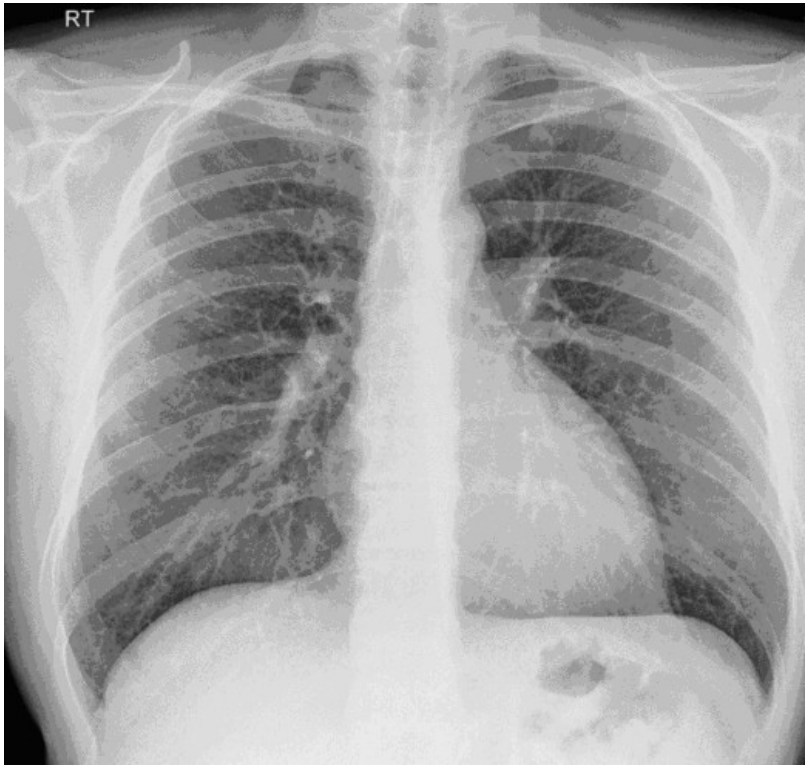

Magnetic Resonance angiography

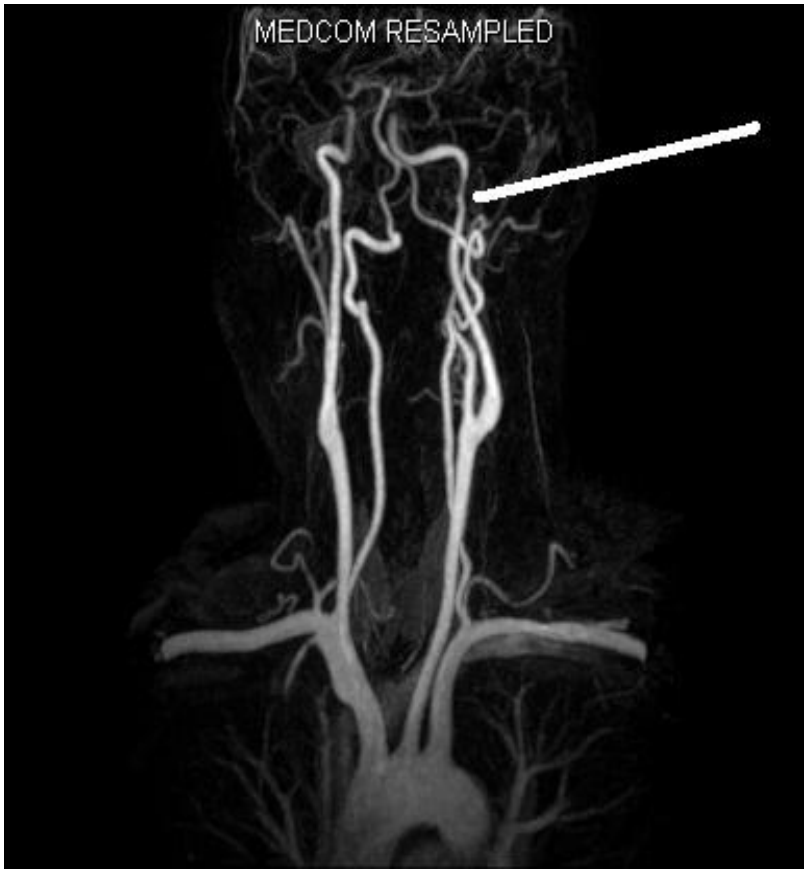

Normal ICA at skull base

Left ICA dissection non occlusive

False lumen (clotted) with crescent

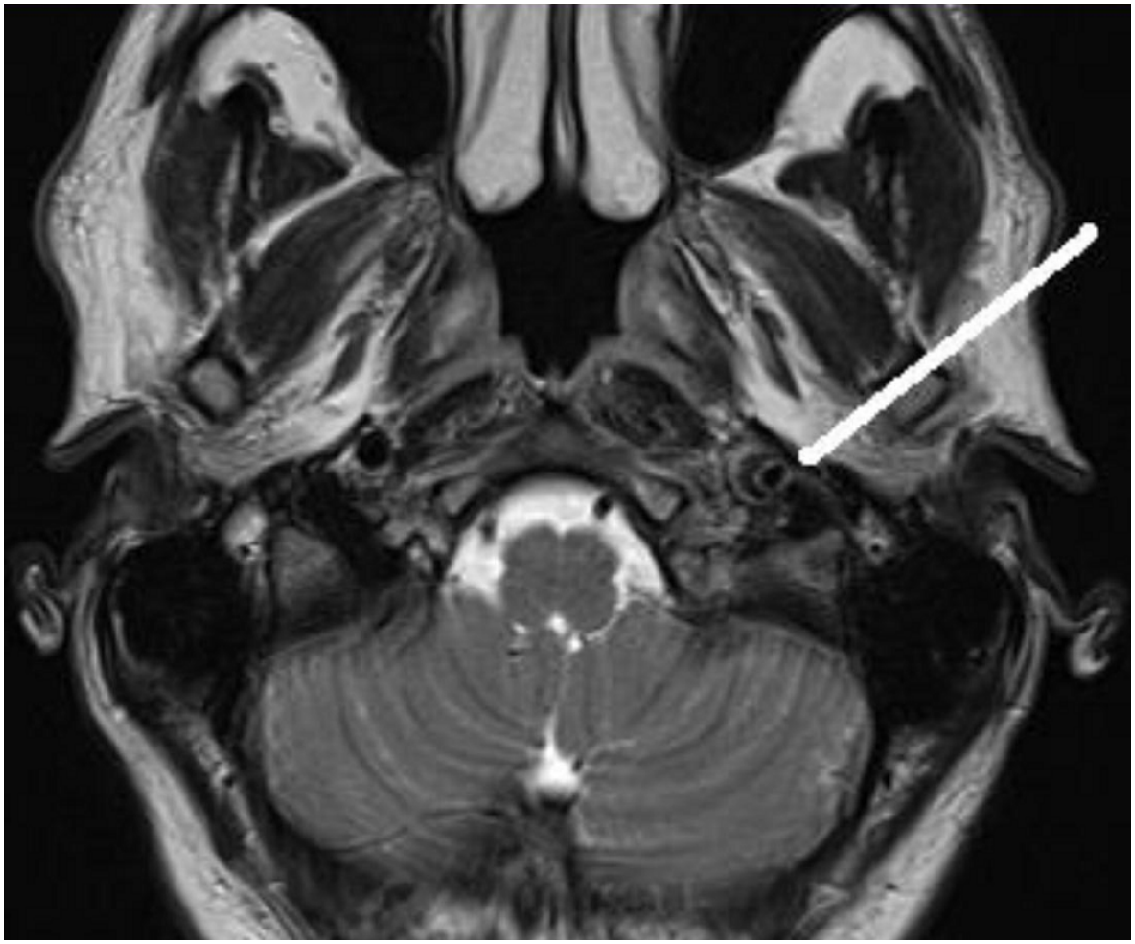

Left carotid narrowed

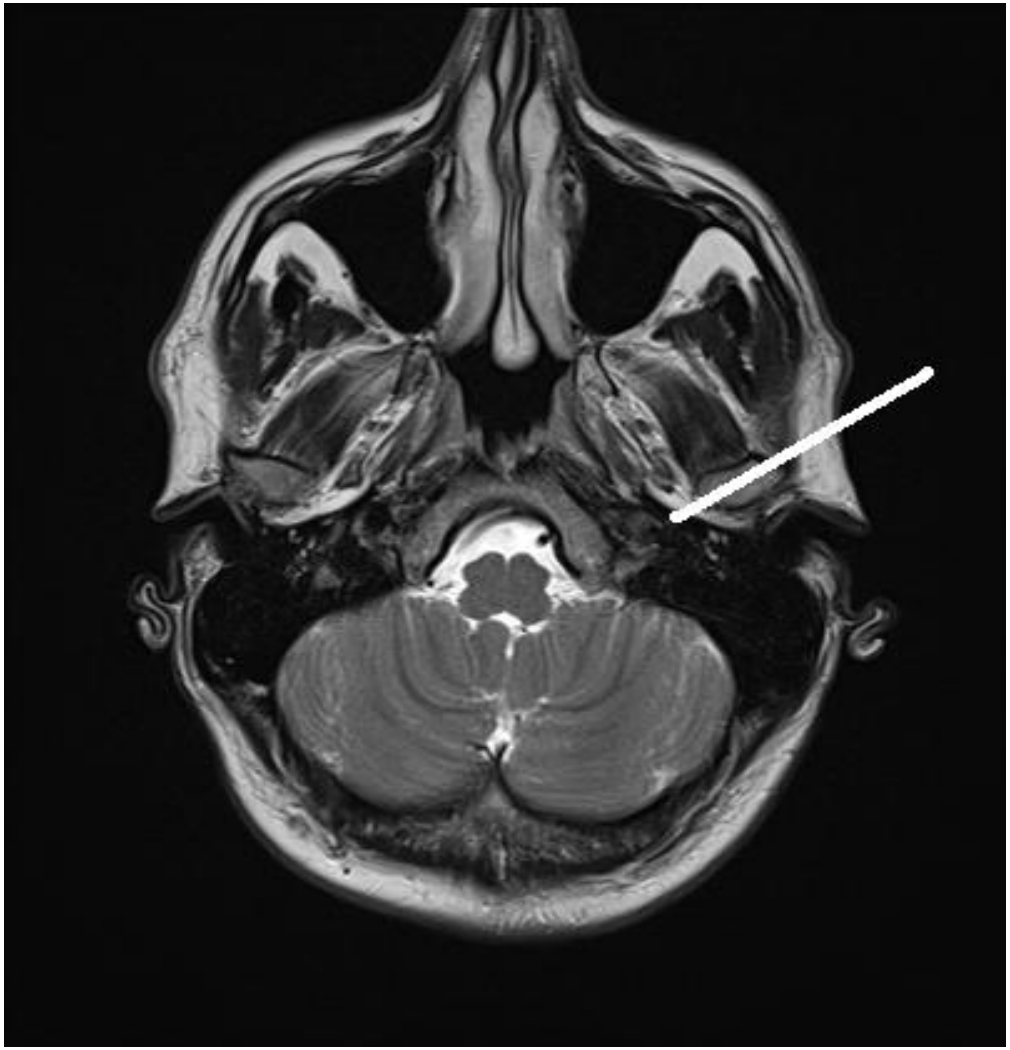

Normal ICA in cavernous sinus

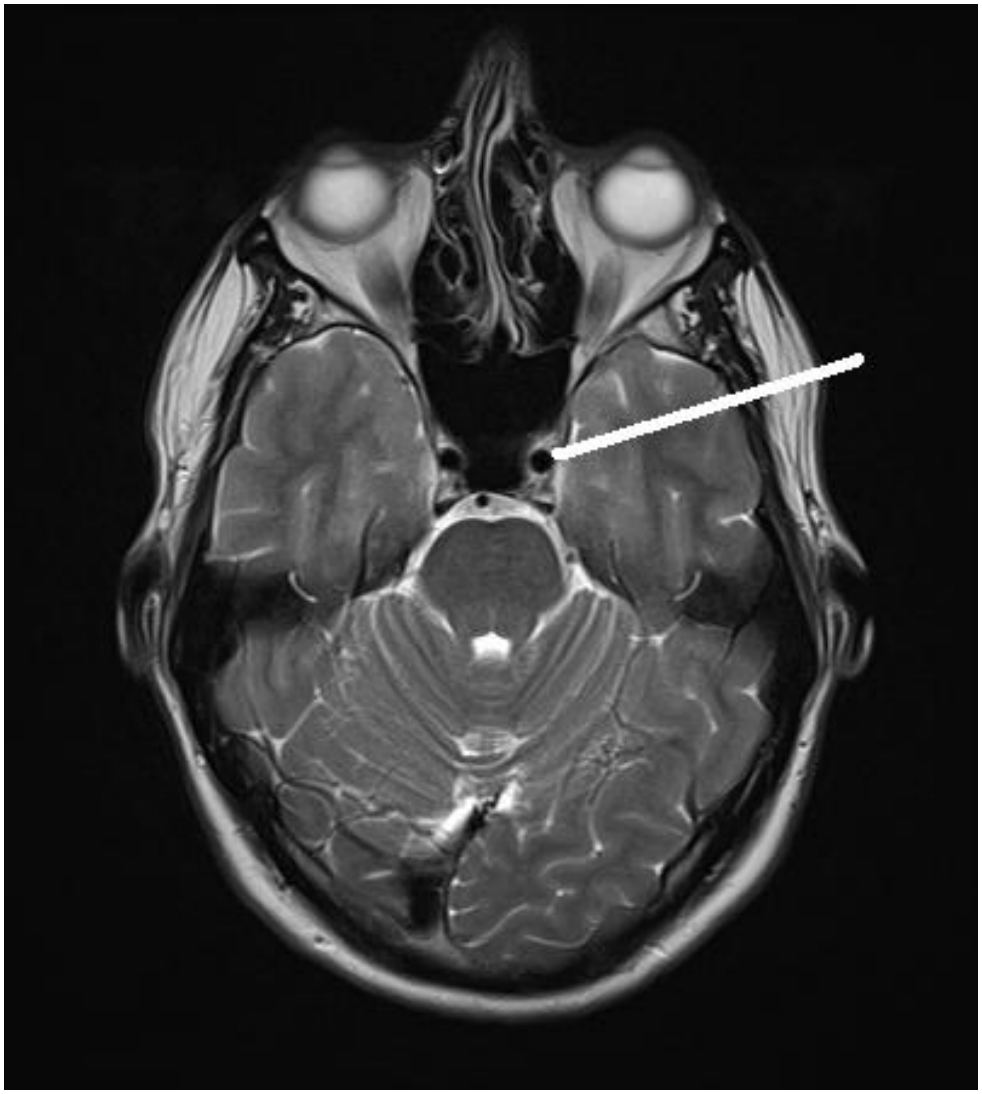

Horner's

- Oculosympathetic paresis
  - Ptosis
  - Miosis
  - Ipsilateral anhidrosis (1st and 2nd lesion)
  - Heterochromia
  - Does not dilate with cocaine 4%

PHARMACOLOGICAL DIAGNOSIS AND LOCALIZATION OF HORNER SYNDROME

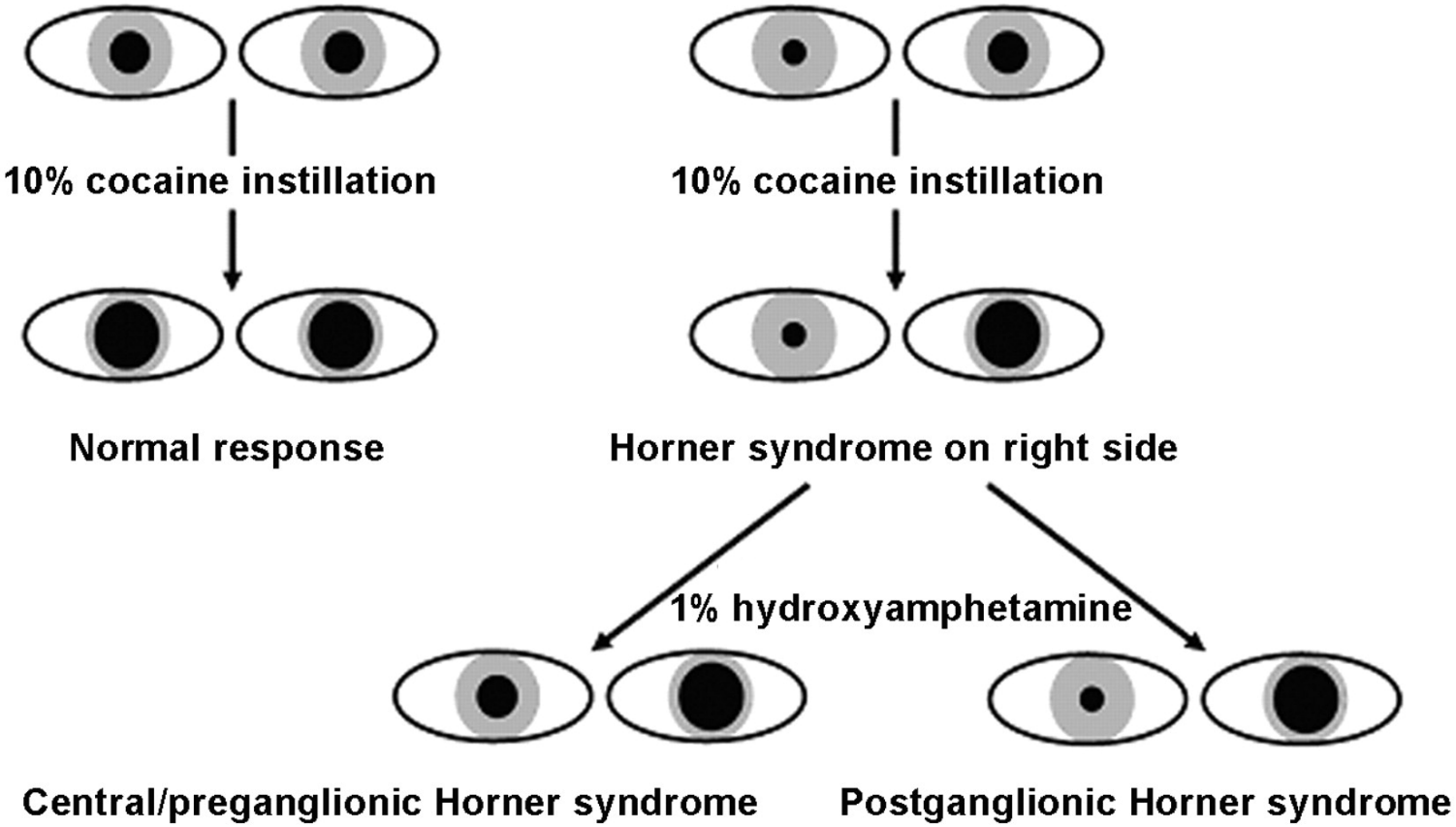

Lee J H et al. AJR 2007;188:W74-W81

Causes of Horner's pupil

- Central – B/S lesions (tumours, vascular and MS) Syringomyelia, Lat. Med. Syndrome.
- Preganglionic – Pancoast tumour, Carotid & Aortic aneurysms, Neck lesions/trauma.
- Postganglionic – Cluster headaches, Nasopharyngeal tumours, Otitis media, Cavernous sinus mass and ICA disease.
- Miscellaneous – Congenital (brachial plexus injury) Idiopathic.

Testing

- Apraclonidine (0.5% or 1%)
  - Alpha-receptor agonist
  - Denervation supersensitivity of the iris dilator
  - Reversal of anisocoria = positive

Am J Ophthalmol. 2006 Sep;142(3):469-74.
Efficacy of apraclonidine 0.5% in the diagnosis of Horner syndrome in pediatric patients under low or high illumination.
Chen PL, Hsiao CH, Chen JT, Lu DW, Chen WY.

TABLE 1. Data on Patients With Horner Syndrome

Patient	Age (ys)	Gender	Etiology	Duration (ys)	Cocaine Test	Ophthalmologic Finding
1	2.5	M	Birth trauma	2.5	+	PMI
2	8	M	Birth trauma	8	+	PMI
3	1.5	M	Birth trauma	1.5	+	PMI
4	3	M	Idiopathic	3	+	PMI
5	5	F	Idiopathic	5	+	PMI
6	18	M	Idiopathic	10	+	PM
7	10	M	Idiopathic	10	+	PMI
8	16	M	Head trauma	9	+	PM
9	1.2	F	Neuroblastoma	0.5	+	PM
10	6	M	Surgical trauma	2	+	PM

+ = positive result; P = ptosis; M = miosis; I = iris heterochroma.

Learning Points

- Horner syndrome may be the first symptom of a potentially serious condition
- Painful Horner Sx should suggest silent carotid disection until proven otherwise
- MRI and MRA are the procedures of choice
- ICA disection is life threatening an carries risk of disabling stroke
- Anticoagulation


Thank you